
PAROTIDECTOMY

STEP 1 INCISION AND ELEVATION OF SKIN FLAP

Create a modified Blair **Figure 1** or facelift incision. **Figure 2**

Raise a superficial cervico-fascial flap between the Superficial Musculo Aponeurotic System (SMAS) layer and the parotid fascia until the anterior border of the parotid gland is reached. **Figure 3**

STEP 2 IDENTIFICATION OF GREAT AURICULAR NERVE

Identify the great auricular nerve (GAN) and the external jugular vein (EJV) at the anterior border of sternocleidomastoid muscle (SCM) .

The posterior branch of the GAN is dissected toward the ear lobe and preserved. The anterior branch of the GAN

is divided. **Figure 4**

STEP 3 SEPARATE PAROTID GLAND FROM SCM

The anterior border of SCM is skeletonized and separated from the parotid gland.

The posterior belly of the digastric muscle is identified by retracting the parotid gland superiorly.

STEP 4 IDENTIFICATION OF LANDMARKS FOR FACIAL NERVE

The tragal pointer is identified by following the cartilaginous external auditory canal medially.

Identify all the following **landmarks for the facial nerve.**

PAROTIDECTOMY

- Tragal pointer. The facial nerve is 1 cm deep and inferior.
- Tympanic ring.
- Tympanomastoid suture line. This line leads directly to stylomastoid foramen medially.
- Posterior belly of digastric muscle. The facial nerve is at the same depth, just above the muscle.
- Palpate the styloid process. The facial nerve is located in the angle between the styloid process and the posterior belly of the digastric muscle. The nerve crosses the styloid process more anteriorly.

Identify the main trunk of the facial nerve by blunt dissection with a fine haemostat.

Figure 5

STEP 5 DISSECT FACIAL NERVE FROM PAROTID GLAND

Identify the Pes Anserinus then trace the upper and lower divisions of the facial nerve anteriorly.

Use fine curved blunt tipped scissors for the remainder of the nerve dissection. Tunnel and spread the tissues overlying the facial nerve and its branches and divide the parotid tissue overlying the nerve. It is important to dissect directly on the nerve so as not to lose sight of it. **Never** divide parotid tissue beyond exposed facial nerve. Wearing loupes (e.g. with 2.5x magnification) assists with the dissection and enables the surgeon to

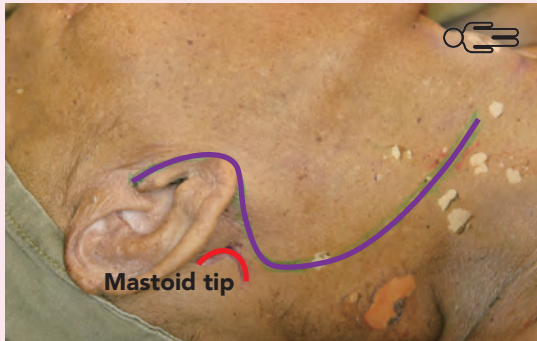


Figure 1
Modified Blair incision

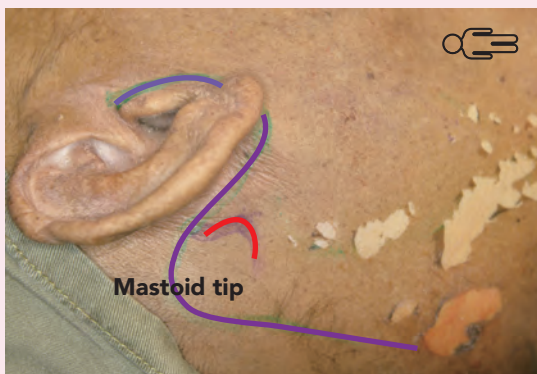


Figure 2
Facelift incision

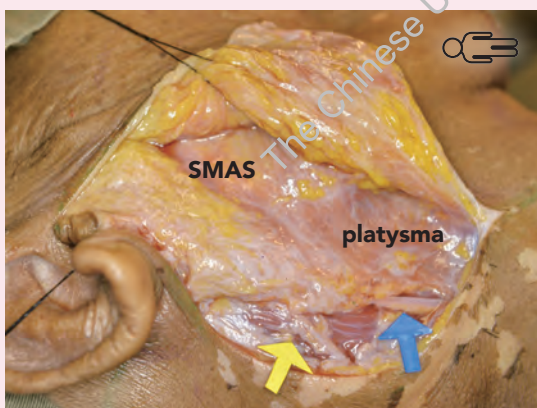


Figure 3
SMAS is continuous with platysma muscle, GAN (yellow arrow) and External jugular vein (blue arrow)

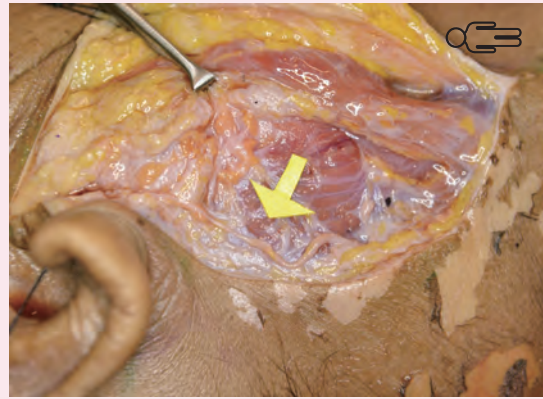


Figure 4
Posterior branch of GAN dissected toward the ear lobe (yellow arrow)

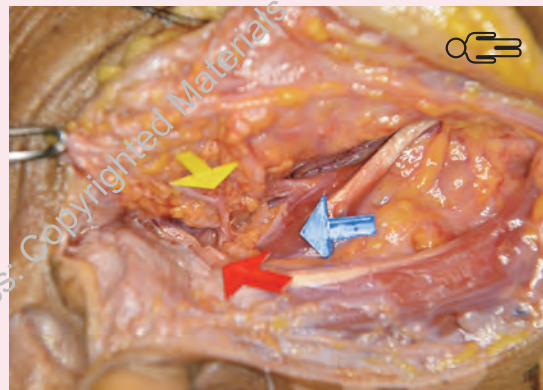


Figure 5
Main trunk of facial nerve (yellow arrow) with reference to posterior belly of digastric (blue arrow) and tragal pointer (red arrow)

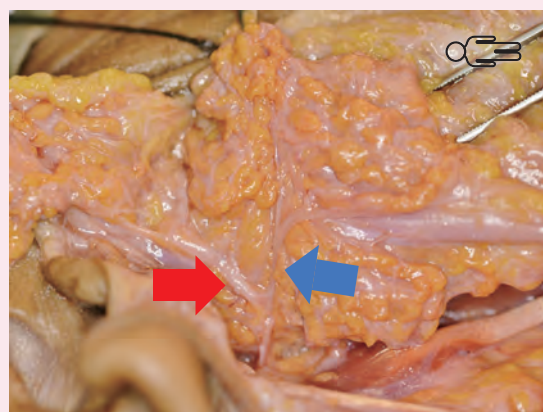


Figure 6
Upper (red arrow) and lower (blue arrow) divisions of facial nerve

PAROTIDECTOMY

better distinguish between blood vessels and nerves. Use bipolar diathermy and fine silk ties for haemostasis. **Figure 6**

Divide the parotid fascia and parotid tissue superiorly and inferiorly to release the parotid posteriorly and to permit anterior mobilisation of the gland/tumour.

Dissect carefully along each branch and strip the superficial lobe off the branches of the facial nerve.

Identify the retromandibular vein as it crosses medial to the facial nerve. **Figure 7**

Remove the tumour with a cuff of the superficial parotid lobe.

TOTAL PAROTIDECTOMY OR DEEP LOBE TUMOUR

STEP 6 FREE UP THE FACIAL NERVE

Taking care to avoid unnecessary traction on the nerve, identify, dissect and circumferentially free up the facial nerve from the underlying deep lobe or tumour to provide access to the deep lobe.

The tumour can be delivered either between the branches or below the facial nerve.

The deep lobe of the parotid/tumour is bordered medially by fat of the parapharyngeal space and can be delivered from the parapharyngeal space by blunt dissection.

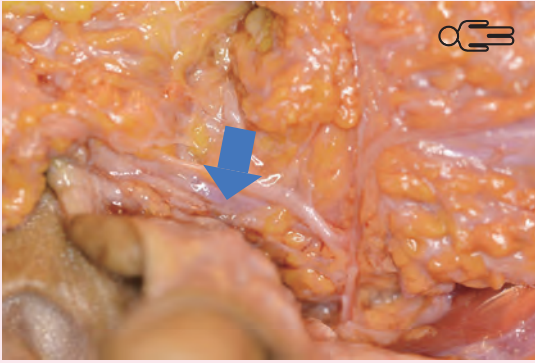


Figure 7

Retromandibular vein (blue arrow) deep to the facial nerve

KEY POINTS

1. Raise a flap deep to the SMAS.
2. Preserve the posterior branch of the GAN.
3. Locate all landmarks for identifying the facial nerve.
4. Use a fine haemostat superficial to the nerve and identify the Pes Anserinus and subsequent divisions.
5. Only divide tissue overlying the nerve with the nerve in view at all times.
6. For total parotidectomy, minimal traction on the facial nerve is the key to avoid prolonged facial nerve paresis.